

## CHAPTER 2.4.5.

# BOVINE SPONGIFORM ENCEPHALOPATHY

---

### SUMMARY

**Description of the disease:** Bovine spongiform encephalopathy (BSE) is a fatal neurological disease of adult cattle that was first recognised in Great Britain (GB) and that has been identified in classical (C-type BSE) and atypical forms. Both C-type BSE and atypical forms have been detected in cattle indigenous to most European countries, the Americas, and Asia and the Pacific. BSE is a transmissible spongiform encephalopathy (TSE), or prion disease. The archetype for this group of diseases is scrapie of sheep and goats (see Chapter 2.7.12 Scrapie).

The C-type BSE epizootic resulted from oral exposure to prions in the ruminant-derived protein of meat-and-bone meal and milk replacers included in animal feedstuffs. As a result of control measures, C-type BSE epizootics are in decline.

Experimental transmissibility of all forms of BSE to cattle has been demonstrated. The C-type BSE agent is also believed to be the common source, via dietary routes, of TSEs in other ruminant species and felidae. There is evidence of a causal link between the C-type BSE agent and variant Creutzfeldt-Jakob disease (vCJD) in humans. Recommendations for handling BSE-infected material assume that BSE is a zoonosis and manipulations with potentially contaminated material must be performed at an appropriate biosafety and containment level determined by biorisk analysis.

**Identification of the agent:** Clinical C-type BSE had a peak incidence in cattle aged between 4 and 5 years during the height of the epizootic. The clinical course is variable but can extend to several months. Overt clinical signs are distinctive, if differential diagnoses can be eliminated. Early clinical signs may be subtle and mostly behavioural, and may lead to disposal of affected animals before suspicion of BSE is triggered. In countries with a statutory policy toward the disease, clinically suspect cases must be killed, the brain examined and the carcass destroyed. Now, in most countries involved, active surveillance at abattoirs and the screening of fallen stock identifies preclinical cases and cases in which there may have been unrecognised clinical signs. No diagnostic test is currently available for live animals.

A disease-specific partially protease-resistant, misfolded isoform of a membrane protein PrP<sup>C</sup>, originally designated PrP<sup>Sc</sup>, has a critical importance in disease pathogenesis. According to the prion hypothesis, PrP<sup>Sc</sup> is the principal or sole component of the infectious agent. Confirmation of the diagnosis is reached by immunohistochemical (IHC) and/or immunochemical detection of PrP<sup>Sc</sup> in brain tissue. Atypical forms of BSE are believed to occur spontaneously in all cattle populations at a very low rate, and has only been identified in older cattle. They have been detected in many countries, but only as an incidental finding when conducting intensive surveillance for C-type BSE. The discrimination of atypical phenotypes from the classical BSE type is based on Western immunoblot banding pattern and bioassay characterisation.

Commercial diagnostic kits for BSE are available and are used in many countries; similarly a number of anti-PrP antibodies form the basis of many diagnostic methods. Some are available commercially, or from OIE Reference Laboratories or other laboratories with active TSE surveillance programmes.

**Serological tests:** Specific immune responses have not been detected in TSEs.

**Requirements for vaccines:** There are no vaccines available.

## A. INTRODUCTION

For up-to-date information on the distribution of the disease, please consult the OIE World Animal Health Information Database ([http://www.oie.int/wahis\\_2/public/wahid.php/Wahidhome/Home](http://www.oie.int/wahis_2/public/wahid.php/Wahidhome/Home))

### 1. Description of the disease

Bovine spongiform encephalopathy (BSE) is a fatal prion disease of cattle and may present clinically with signs of central nervous disease, such as apprehension, hyper-reactivity and ataxia. Confirmatory diagnosis relies on post mortem IHC and immunochemical detection of misfolded prion proteins in the brain.

Transmission of classical BSE (C-type BSE) occurs through the feeding of BSE prion contaminated meat and bone meal and animal feedstuffs containing meat and bone meal (Wells & Wilesmith, 1995). There is no evidence of horizontal transmission and little data to support vertical transmission (Prince *et al.*, 2003). Epidemiological data and experimental transmission studies indicate that the incubation period is at least 2 years and may extend beyond a decade. The course of disease is usually subacute to chronic, and affected animals display progressive neurological signs. There is no effective treatment and affected animals will inevitably die if the disease is left to run its course.

Clinical C-type BSE occurs in adult cattle (ranging between 20 months and 22 years in the UK). During the main epizootic most cases were observed in dairy cattle aged 4–6 years. Subsequently the impact of effective controls has been reflected in an increasing age at onset of clinical disease. BSE has an insidious onset and usually a slowly progressive course (Konold *et al.*, 2004; Wilesmith *et al.*, 1992). Occasionally, a case will present with acute signs and then deteriorate rapidly, although frequency of observation is a significant factor in determining early clinical signs. Presenting signs, though variable, usually include changes in behaviour and temperament, hyper-reactivity and incoordination. Affected cows may be reluctant to enter the milking parlour or may kick vigorously during milking, which is often the first observed sign. In dry cows especially, hind-limb incoordination and weakness can be the first clinical features to be noticed. The most commonly reported nervous signs have been apprehension, pelvic limb ataxia, and hyperaesthesia to touch and sound. Startle responses to external stimuli, which are repeatable, are frequent and thus used to support the clinical diagnosis in suspect BSE cases (Konold *et al.*, 2004). Affected cows will sometimes stand with low head carriage and the neck extended, an arched back or wide-based hind limbs. A tremor of the head may also be visible. Abnormalities of gait, such as incoordination and hypermetria, are usually confined to the hind limbs and are most readily appreciated when cattle are observed at pasture. With advancing severity of locomotor signs, generalised weakness, resulting in falling and recumbency, can dominate the clinical picture. General clinical features of loss of bodily condition and reduction in milk yield often accompany nervous signs as the disease progresses. There has been no change in the clinical picture of C-type BSE over the course of the epizootic in the UK (Konold *et al.*, 2004; Wilesmith *et al.*, 1992). Clinical signs are essentially similar in other countries where C-type BSE has occurred. The protracted clinical course, extending usually over a period of weeks or months, would eventually require culling on welfare considerations. However, a statutory policy to determine the BSE status of a country requires compulsory notification and diagnostic investigation of clinically suspect cases, their culling and post-mortem examination of the brain. Early in the disease course, the signs may be subtle, variable and nonspecific, and thus may prevent clinical diagnosis on an initial examination. Continued observation of such equivocal cases, together with appropriate clinical pathology procedures to eliminate differential diagnoses, especially metabolic disorders, will establish the essential progression of signs. Subtle signs may sometimes be exacerbated following stress, such as that caused by transport.

Video clips of cattle affected by BSE may be downloaded from the web site of the OIE Reference Laboratory for BSE in the UK<sup>1</sup>, which also provides DVD or videotape footage upon request.

Little is known about the clinical presentation of naturally occurring atypical BSE as most of these cases were detected by active surveillance of fallen stock or apparently healthy cattle, and correlation of laboratory diagnostic data with clinical histories is lacking. An interesting common feature is that cases of atypical BSE were almost exclusively detected in cattle older than 8 years. Data from experimental intracerebral inoculation of cattle suggest that the clinical signs in H- and L-type BSE may include those observed in C-type BSE, but dullness and difficulty in rising are also prominent features of the clinical presentation in these animals (Konold *et al.*, 2012).

### 2. Causal pathogen

Without an isolatable causal agent, cases can only be conclusively confirmed post-mortem by the accumulation in the central nervous system (CNS) of abnormal prion protein (PrP<sup>Sc</sup>, PrP<sup>d</sup> or PrP<sup>res</sup>), a partially protease-resistant

---

1 The laboratory is also the European Commission (EC) Transmissible Spongiform Encephalopathies (TSEs) European Union Reference Laboratory (EURL). All its Web Resources can be found at: <http://www.tse-lab-net.eu/>

isoform of a host-encoded protein (PrP<sup>C</sup>). The prion hypothesis proposes that the agent is composed entirely of PrP<sup>Sc</sup>, which is capable of inducing conversion of PrP<sup>C</sup>. Pathological and bioassay characterisation showed that the BSE epizootic was sustained by a single strain, and consistently distinctive neuropathology and PrP<sup>Sc</sup> molecular profiles in clinically affected animals were the basis for the case definition of C-type BSE. Since 2003, reports of variant pathology or molecular characteristics in aged cattle from many countries have indicated agent strain variation (Biacabe *et al.*, 2004; Casalone *et al.*, 2004).

So far, approximately 100 atypical BSE cases have been recognised that differ in their molecular profiles by Western immunoblotting from C-type BSE. Bioassay data support the hypothesis that these strains are biologically distinct from C-type BSE (Beringue *et al.*, 2006; Lombardi *et al.*, 2008; Okada *et al.*, 2011). The two atypical forms are operationally defined as BASE (bovine amyloidotic spongiform encephalopathy) or L-type, and H-type BSE based on the lower or higher mass respectively of the unglycosylated PrP<sup>Sc</sup> fragment in Western immunoblots compared to C-type BSE (Casalone *et al.*, 2004; Jacob *et al.*, 2007).

### 3. Zoonotic risk and biosafety requirements

The emergence of variant Creutzfeldt-Jakob disease (vCJD) in humans has been causally linked to ingestion of C-type BSE (Bruce *et al.*, 1997). It is not known whether atypical cases are causally linked to forms of human prion diseases. Recommended safety precautions for handling the agent are based on the assumption that all forms of BSE are zoonotic. Biocontainment for necropsies and tissue handling should be risk-based and compliant with relevant national regulations; any procedure creating aerosols must be performed at an appropriate biosafety and containment level determined by biorisk analysis (see Chapter 1.1.4 *Biosafety and biosecurity: Standard for managing biological risk in the veterinary laboratory and animal facilities*), and the laboratory must comply with national biocontainment and biosafety regulations to protect staff from exposure to the pathogen. Recommended physical inactivation is by porous load autoclaving at 134°C–138°C for 18 minutes at 30 lb/in<sup>2</sup> (208 kPa or 2.2 bar). However, total inactivation may not be achieved under certain conditions, such as when the test material is in the form of a macerate, of high titre or when the agent is protected within dried organic matter. Disinfection of potential fomites is carried out using sodium hypochlorite containing 2% available chlorine, or 2 N sodium hydroxide, applied for more than 1 hour at 20°C for surfaces, or overnight for equipment.

### 4. Differential diagnosis

For differential diagnosis all types of neurological diseases in cattle should be taken into account, including infectious encephalitis, metabolic disorders (ketosis, hypomagnesaemia), toxicoses, neoplasia and trauma.

## B. DIAGNOSTIC TECHNIQUES

**Table 1.** Test methods available for the diagnosis of bovine spongiform encephalopathy and their purpose

Method	Purpose					
	Population freedom from infection	Individual animal freedom from infection prior to movement	Contribute to eradication policies	Confirmation of clinical cases	Prevalence of infection – surveillance	Immune status in individual animals or populations post-vaccination
<b>Agent identification<sup>2</sup></b>						
<b>Immunohistochemistry</b>	n/a	n/a	++	+++	++	n/a
<b>Western immunoblot</b>	n/a	n/a	++	+++	++	n/a

<sup>2</sup> A combination of agent identification methods applied on the same clinical sample is recommended.

Method	Purpose					
	Population freedom from infection	Individual animal freedom from infection prior to movement	Contribute to eradication policies	Confirmation of clinical cases	Prevalence of infection – surveillance	Immune status in individual animals or populations post-vaccination
<b>Rapid screening tests</b>	n/a	n/a	+++	+	+++	n/a
<b>Histo-pathology</b>	n/a	n/a	+	+	+	n/a

Key: +++ = recommended method; ++ = suitable method; + = may be used in some situations, but cost, reliability, or other factors severely limits its application; – = not appropriate for this purpose; n/a = not applicable. Although not all of the tests listed as category +++ or ++ have undergone formal validation, their routine nature and the fact that they have been used widely without dubious results, makes them acceptable.

## 1. Identification of the agent

There is no method capable of confirming the presence of BSE in the live animal. Identification of the ‘agent’ begins with clinical suspicion of disease, the post-mortem demonstration of histopathological changes or PrP<sup>Sc</sup> accumulation in a suspect animal, or in a non-suspect animal through active surveillance. The nature of the ‘agent’ itself remains hypothetical, and it cannot therefore be isolated for diagnostic purposes. However, PrP<sup>Sc</sup> is widely accepted as a consistent disease marker, and, with the exception of clinical examination and histopathology, all current diagnostic methods are based on the demonstration of this protein.

In the absence of *in-vitro* methods for isolation of the causative agent, disease can be confirmed by demonstrating characteristic TSE-specific vacuolation by histopathology at several different levels of the brain. Histopathological diagnosis based on examination of a single section of medulla oblongata (at the level of the obex) has been validated against more extensive examination of the brainstem. This simplified approach enables the sampling of brainstem removed via the *foramen magnum*, using customised instrumentation, instead of whole brain removal. However, immunochemical methods of disease-specific PrP detection, including IHC techniques and Western immunoblot, are recommended to confirm the diagnosis and improve diagnostic sensitivity in early or autolysed cases. The more rapidly performed *in-vitro* methods, such as enzyme-linked immunosorbent assay (ELISA), for the detection of PrP<sup>Sc</sup> has led to a variety of ‘rapid’ tests, which are now the principal screening tools for active surveillance. Such tests provide a preliminary diagnosis from which positive or inconclusive results are subject to examinations by IHC or Western immunoblot confirmatory methods. Rapid tests are currently the main approach by which cases are detected and their wider use as part of the confirmatory process has been agreed, providing that one of the two tests used is a Western immunoblot (<http://www.tse-lab-net.eu/documents/tse-oie-guide.pdf>). All currently recognised forms of BSE are detectable by these methods although a full sensitivity and specificity evaluation for atypical forms (H- and L-types) has not been carried out.

The choice of any particular method will depend on the context of its use. Contexts will extend from confirmation of clinical suspects to the screening of healthy populations for evidence of covert or preclinical disease. The case definition adopted will also differ according to whether the diagnostic method is to be applied for confirmation or for screening. Care should be taken in the interpretation of diagnostic data using methodologies that do not enable careful cross-referencing with the standards for confirmatory diagnosis that are defined here. Without appropriate comparison with previously published criteria defining the BSE phenotype, and in the absence of transmission studies, diagnostic results that claim the identification of a new strain may be premature. Quality control (QC) and quality assurance (QA) are essential parts of the testing procedures and advice can be supplied by the OIE Reference Laboratories. Whether BSE-infected animals are identified by passive or active surveillance, it is good practice to detect and confirm disease by a combination of at least two test methods. The primary test can be one of the confirmatory test methods described below or a rapid test, but it is important to apply a secondary test to confirm a positive or inconclusive primary test result. Where there is a conflict between primary and secondary test results, further tests using immunohistochemistry or Western immunoblot should be applied or samples should be submitted to an OIE Reference Laboratory for resolution.

### 1.1. Sample preparation

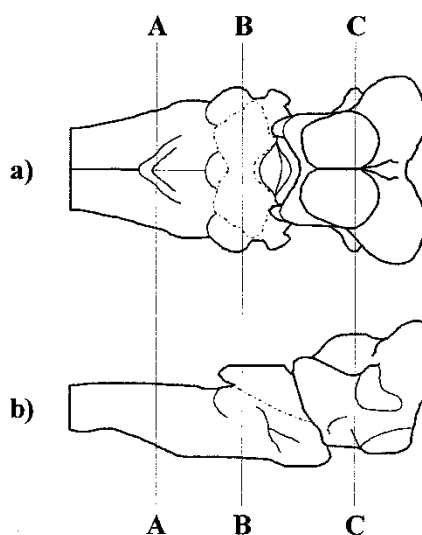
The BSE status of a country, the relative implementation of passive and active surveillance programmes and the diagnostic methods applied, will all influence sampling strategy.

In all circumstances of passive surveillance of neurological disease in adult cattle **where the occurrence of BSE within a country or state has not been established or is of low incidence**, it is recommended that clinically suspect cases are subjected to a standard neuropathological approach in which the whole brain is sampled, and a range of representative areas examined. Cattle suspected of having the disease should be killed with an intravenous injection of a concentrated barbiturate solution preceded, if necessary, by sedation. The brain should be removed as soon as possible after death by standard methods. There are no gross lesions associated with BSE, so if any are observed when the brain is removed, these should be specifically sampled to facilitate differential diagnosis.

Care must be taken to preserve suitable fixed and fresh brain samples for the immunohistochemical and immunochemical detection of PrP<sup>Sc</sup>. Departure from this approach of collecting and retaining the entire brain may prevent appropriate characterisation of the case, to confirm whether or not it is typical of BSE.

Histopathology and IHC examinations are carried out initially on a single block (0.5–1.0 cm in width) cut at the obex of the medulla oblongata (Fig. 1a and b, level A–A representing the centre of the block for examination), which should be fixed for a minimum of 3–5 days (dependent on block thickness) in 4% formaldehyde solution (i.e. 10% formal saline or 10% normal buffered formalin [NBF]). To decrease infectivity, fixed tissues may be immersed in 98% formic acid for one hour to reduce the prion infectivity, then washed for 30 minutes in tap water. It should be noted that this may reduce the range of further tests that could be applied for classification unless fresh frozen material is also available. Subsequent histological processing should be by conventional paraffin wax embedding methods for neural tissue. (An example of appropriate processing methods can be found on TSE-LAB-NET (<http://www.tse-lab-net.eu/documents/tse-oie-rl-prp.pdf>.)

Fresh material for the immuno-detection of PrP<sup>Sc</sup> should be taken initially as a hemisection of the medulla at the level of the obex, or as a complete coronal section (2–4 g), immediately rostral, or caudal, to the obex block taken for fixation. All other brain areas should be subdivided by a sagittal paramedian cut (3–5 mm off the median). The smaller portion is reserved for the detection of PrP<sup>Sc</sup> by immunochemical methods (e.g. immunoblot) and is stored frozen prior to testing (if testing is not done immediately after sampling). After sampling of the obex region for fixation and sampling of fresh tissue, the larger portion of the brain tissue is placed, intact, in approximately 4–6 litres of 10% formalin fixative, which should be changed twice weekly. After fixation for 2 weeks, if further investigation is necessary, the brain can be cut into coronal slices. The fixation time may be shortened by cutting the fresh brainstem (detached from the rest of the brain) into smaller coronal pieces, similarly



**Fig 1.** Brainstem after the removal of the cerebellum, from a) dorsal, and b) lateral aspects.

*Recommended levels at which sections should be taken:*

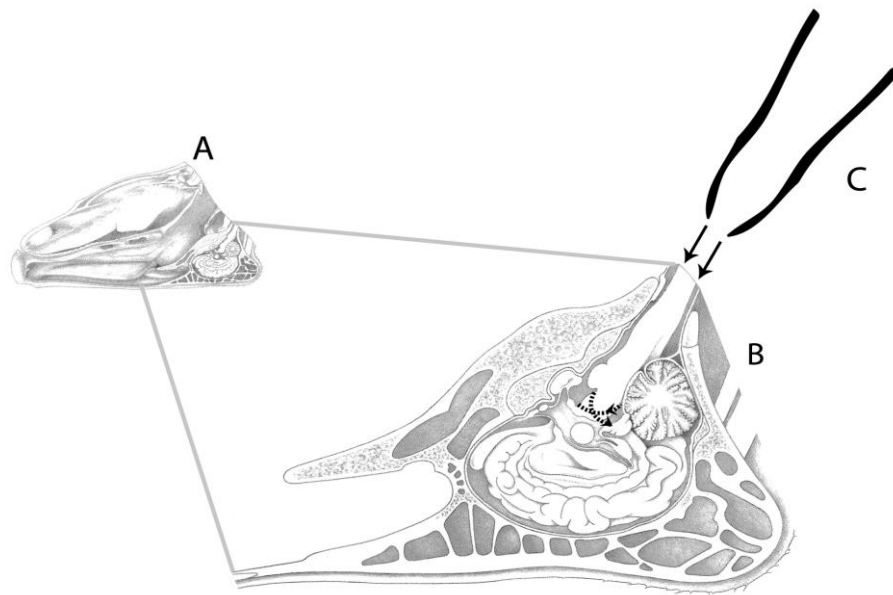
*A–A = medulla, at the obex; B–B = medulla through caudal cerebellar peduncles;*

*C–C = midbrain through rostral colliculi.*

to the initial removal of the obex region, but leaving intact the remaining diagnostically important cross-sectional areas at the levels of the cerebellar peduncles and the rostral colliculi (Figure 1a and b, levels B–B and C–C, respectively). Depending on some other factors (temperature, agitation, thickness of tissue block, use of microwave) the fixation time for these smaller pieces of brain may be reduced. However, evaluation of the effects of these kinds of accelerated fixation processes on subsequent IHC protocols needs to satisfy proficiency testing standards. The other formol-fixed parts of the brain may be used for differential diagnosis after completing the standard 2 weeks of fixation.

**When the occurrence of BSE in a particular country has been established in the indigenous cattle population**, and there is evidence that the distribution of lesions and other aspects of disease phenotype are consistent with those described for classical BSE, it is adequate, although not ideal, for disease confirmation and monitoring purposes, to remove the brainstem alone.

This can be achieved via the *foramen magnum* without removal of the calvarium (Fig. 2). This will reduce the amount of fixative required and the time and equipment needed, thereby lowering costs and improving safety. The major target areas for histological examination can still be maintained. This method allows for collecting and examining a large number of samples for passive surveillance or for an active surveillance programme in abattoirs and on fallen stock animals. The brainstem is dissected through the *foramen magnum*, without opening the skull, by means of a specially designed spoon-shaped instrument with sharp edges around the shallow bowl. Such instruments are available commercially. It is possible that variations in technique, including orientation, are required with different forms of the instrument, and it is important to train operators once there is agreement on equipment to be used. This training should include information on the cross-sectional distribution of PrP<sup>Sc</sup> in the brainstem, and the need for the accurate sampling and preservation of the diagnostic target areas (see below).



**Fig. 2.** After the head has been removed from the body by cutting between the atlas vertebra and the occipital condyles of the skull, it is placed on a support, ventral surface uppermost (A), with the caudal end of the brainstem (medulla oblongata) visible at the foramen magnum (see B, expanded drawing of cranium).

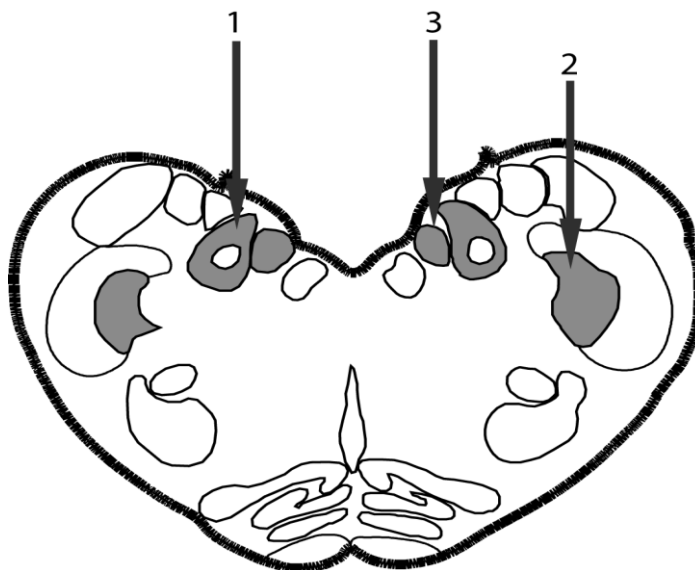
The instrument (C) is inserted through the foramen magnum between the dura mater and the ventral/dorsal aspect (depending upon the specific approach) of the medulla and advanced rostrally, keeping the convexity of the bowl of the instrument applied to the bone of the skull and moving with a side-to-side rotational action.

This severs the cranial nerve roots without damaging the brain tissue. The instrument is passed rostrally for approximately 7 cm in this way and then angled sharply (i.e. toward the dorsal/ventral aspect of the brainstem, depending on the approach) to cut and separate the brainstem (with some fragments of cerebellum) from the rest of the brain. The instrument, kept in the angled position, is then withdrawn from the skull to eject the tissue through the foramen magnum.

**Where the index case is identified through active surveillance**, the necessary brain areas for full phenotypic characterisation are unlikely to be available. In most countries, brainstem alone is collected, even before the first confirmation of BSE. Provision should be made for heads that have been sampled in the course of active surveillance to be retained until the outcome of initial testing is available. This would enable comprehensive sampling of the brain of positive animals in retrospect for the characterisation of cases. This is particularly important if in-house tests that are not subject to external quality assurance are used and where, in the absence of direct comparison with the methods described here, claims are made that new phenotypes have been identified. Where rapid immunoassays are used as the primary surveillance tool it is necessary to make material available for further morphological (including immunohistochemistry) and molecular examination that would allow identification of disease phenotype in the absence of a diagnosis of BSE having ever been made in that country.

#### 1.1.1. Sampling of brainstem in active surveillance with use of rapid tests

The sampling and processing of brain tissue for use in any rapid test should be carried out precisely as specified by the supplier or manufacturer of the test method or kit. Details of this procedure vary from method to method and should not be changed without supportive validation data from the manufacturer for the variant methodology. The preferred sample for immunoassay should be at, or within 1.0 cm rostral, or caudal to, the obex, based on the caudo-rostral extent of the key target sites (Fig. 3) for demonstration of PrP<sup>Sc</sup> accumulations and the evaluation of sampling for rapid tests. The choice of target site has to take into account the subsequent method of confirmation. At least a hemi-section of the medulla at the level of the obex should be kept intact for fixation for immunohistochemistry/histology (as described above) should a positive result require confirmation. Sampling the medulla rostral or caudal to the obex for rapid testing does not compromise examination by histological or IHC means. However, to obtain comparable samples for rapid *and* confirmatory testing, sampling by hemi-section of the medulla at the level of the obex is preferable. While there is resultant loss of the ability to assess the symmetry of any histopathological lesions (notably vacuolation), this approach is less likely to compromise the more important IHC examination. If hemi-sectioning is adopted however, it becomes critical to ensure that the target sites are not compromised in either sample. For example, the nucleus of the solitary tract and the dorsal motor nucleus of the vagus nerve (target areas for lesions in cattle with BSE) are small, and lie relatively close to the midline (Fig. 3). If sampled tissue is autolysed to the point that anatomical orientation is not possible, an unidentified aliquot can still be taken and tested. A positive result in such cases is still a valid result, but a negative test result cannot be taken to indicate a negative animal, and it should be interpreted with caution and reported with appropriate qualification.



**Fig 3.** Cross section of the bovine brainstem at the level of the obex identifying the key target sites for diagnosis by histopathology and immunohistochemistry in BSE. These are principally the nucleus of the solitary tract [1] and the nucleus of the spinal tract of the trigeminal nerve [2]; but also the dorsal motor nucleus of the vagus nerve [3]. It follows that material taken for application of a rapid test must also include representation of these areas.

Inaccurate hemi-sectioning could result in the complete loss of a target area for confirmatory testing, and could compromise a surveillance programme. Failure to accurately sample target areas may also arise through inappropriate placement of proprietary sampling tools. Such approaches therefore need to be implemented with a very clear policy and monitoring programme for training and quality assurance of sampling procedures, including anatomical positioning, and not just sample weight. Because of the specifically targeted distribution of PrP<sup>Sc</sup>, sample size and location should be as described in the diagnostic kit or, if not specified, at least 0.5 g taken from the diagnostic target areas for all confirmatory tests as detailed in Fig 3. Performance characteristics of the tests may be compromised by autolysis, particularly due to loss of the ability to ensure inclusion of target areas in the sample taken for diagnosis.

## 1.2. Diagnostic examination

### 1.2.1. Histological examination

Histopathology is no longer the diagnostic method of choice for investigation of suspect animals, or the screening of healthy populations. However, an awareness of the histopathological changes is important, to facilitate detection of cases when conducting routine diagnostic histological examinations of cattle brains sampled for reasons other than BSE testing. For differential diagnosis, sections of medulla–obex are cut at 5 µm thickness and stained with haematoxylin and eosin (H&E). If tissue quality permits, the histopathological examination of H&E sections allows confirmation of the characteristic neuropathological changes of BSE (Simmons *et al.*, 1996; Wells & Wilesmith, 1995) by which the disease was first detected as a spongiform encephalopathy. These changes comprise mainly spongiform change and neuronal vacuolation and are closely similar to those of all other animal TSEs, but in BSE the frequent occurrence of neuroparenchymal vacuolation in certain anatomic nuclei of the medulla oblongata at the level of the obex can provide a satisfactory means of establishing a histopathological diagnosis on a single section of the medulla. As in other species, vacuolar changes in the brains of cattle, particularly vacuoles within neuronal perikarya of the red and oculomotor nuclei of the midbrain are an incidental finding (Gavier-Widen *et al.*, 2001). The histopathological diagnosis of BSE must therefore not rely on the presence of vacuolated neurons alone, particularly in these anatomical locations.

Irrespective of the histopathological diagnosis, it is recommended that immunohistochemistry is routinely employed in addition, as unpublished evidence suggests that as many as 5% of clinical suspects (which are negative on H&E section examination for vacuolar changes at the obex) can be diagnosed by IHC examination. Clearly, examination of the medulla–obex does not allow a full neuropathological examination for differential diagnoses, nor does it allow a comprehensive phenotypic characterisation of any TSE. It is for this reason that it is recommended to remove whole brains from all clinical suspects. There are still insufficient data available to describe specific histopathological features of H- or L-type BSE. There are some histological data from Italian researchers on BASE (L-type BSE) (Casalone *et al.*, 2004). Few atypical BSE cases have been found in passive surveillance and it is not possible to obtain whole brains through active surveillance programmes to increase our knowledge in this respect. The poor condition of the brain of fallen stock, where most atypical cases have been identified, also rules out a complete histological examination because of the effects of autolysis. The end-stage pathology of experimental H-type and L-type BSE in a small number of animals following intracerebral inoculation has been described (Konold *et al.*, 2014; Okada *et al.*, 2011).

### 1.2.2. Detection of disease-specific forms of PrP

The universal use of PrP detection methods provides a disease specific means of diagnosis independent of the morphological changes defined by histopathology. Many laboratories now supplement or have replaced histopathological examination by IHC and/or other PrP-detection methods. The detection of accumulations of PrP<sup>Sc</sup> is the approach of choice for surveillance programmes and confirmatory diagnosis. It is possible (but not desirable) to undertake immunohistochemistry for PrP on material that has been frozen prior to fixation (Debeer *et al.*, 2002). Freezing prior to fixation will not compromise the immunoreactivity of a sample, but it may compromise the proper identification of target sites. A positive case will have disease-specific immunolabelling in at least one of the diagnostic target areas (Casalone *et al.*, 2006). For a case to be diagnosed as negative it must be possible to identify the presence of the target areas and to demonstrate that the IHC 'run' was technically successful through appropriate controls. If there is no disease-specific immunolabelling, and target areas cannot be identified, the case should be classified as 'unconfirmed' as opposed to negative. Both H and L-type variants demonstrate accumulation of PrP<sup>Sc</sup> in the medulla at the level of the obex (Casalone, 2006; Konold *et al.*, 2012). The range and morphological appearance of immunolabelling throughout the neuraxis differ from classical BSE, with multiple small plaque-like deposits being



a common feature in variant forms. Differences in the brainstem (obex) are not always pronounced, and cannot be relied on to effectively differentiate or classify cases.

#### 1.2.2.1. Immunohistochemical (IHC) methods

IHC examination for PrP<sup>Sc</sup> accumulation is performed on the same formalin-fixed paraffin-embedded material used for the histopathological diagnosis. Different protocols have been applied successfully to the IHC detection of PrP<sup>Sc</sup> for the diagnosis of BSE and although a standardised IHC method would seem desirable, it might be more important to recognise robust methods that achieve a standardised output, as monitored by participation in proficiency testing exercises, and by comparison with the results of a standardised model method in a Reference Laboratory. The generic technique established for histopathology still applies and it works well in autolysed tissues in which morphological evaluation is no longer possible (Monleon *et al.*, 2003). However, it is imperative to recognise the anatomy of the sample to determine whether or not target areas are represented. This is essential for a negative diagnosis, and may also be pivotal in accurately interpreting equivocal immunolabelling. IHC detection of PrP<sup>Sc</sup> accumulations approximates to the sensitivity of the Western immunoblotting approach for detection of PrP<sup>Sc</sup> (Schaller *et al.*, 1999). In combination with good histological preparations, immunohistochemistry allows detection of PrP<sup>Sc</sup> accumulations and, as this, like the vacuolar pathology, exhibits a typical distribution pattern and appearance. This provides simultaneous evaluation or confirmation of this aspect of the disease phenotype. Current methods are available by reference to the OIE Reference Laboratories.

In contrast to the diagnosis of scrapie of sheep, the limited detection of PrP<sup>Sc</sup> in lymphoid tissues in BSE does not provide any scope for utilising such tissues for preclinical diagnosis by biopsy techniques.

#### 1.2.2.2. Western immunoblot methods

Immunoblotting techniques are carried out on fresh (unfixed) tissue, and can be applied successfully even when tissue is autolysed (Hayashi *et al.*, 2004). The SAF-immunoblot (Stack *et al.*, 2004) was the first such method for use in BSE diagnosis. Western immunoblot has similar diagnostic sensitivity to the IHC techniques, and remains the method of choice, along with immunohistochemistry, for the confirmation of BSE. It is a highly sensitive method using a large mass (ideally 2–4 g) of starting material and several steps to concentrate PrP<sup>Sc</sup>. Alternative less time-consuming and less costly methods are now available. These use less material and are more practical. A range of Western immunoblotting methods are available on TSE-LAB-NET<sup>3</sup> or from the other OIE BSE Reference Laboratories.

While Western immunoblot methodology is now in general use around the world, analytical sensitivity when used to detect PrP<sup>Sc</sup> varies significantly between methods and laboratories. Where in-house methods are preferred to published methods for confirmatory purposes, it is important that they are evaluated as being fit for purpose and validated in consultation with an OIE Reference Laboratory.

OIE and national reference laboratories have established Western immunoblot methods to discriminate H- and L-type variants from classical BSE. Discrimination is based on distinct N-terminal proteinase K cleavage, antibody reactivity and glycosylation pattern of PrP<sup>res</sup> (Jacob *et al.*, 2007). A detailed protocol including diagnostic criteria has been released by the European Union Reference Laboratory and is available online at TSE-LAB-NET<sup>4</sup>.

#### 1.2.2.3. Rapid test methods

Rapid Western immunoblot, lateral flow assays and ELISA techniques have been developed that allow screening of large numbers of brain samples and are commercially available. Such techniques can be performed in a few hours (see EC evaluations of rapid tests for the detection of BSE on known IHC positive and negative sample groups<sup>5</sup>). Tests that have been evaluated and approved for BSE surveillance within the EU are listed in Annex C Chapter X of the TSE

---

3 <http://www.tse-lab-net.eu/>

4 <http://www.tse-lab-net.eu/documents/tse-rl-blot.pdf>.

5 <http://www.tse-lab-net.eu/test.html>

Regulation (EC 999/2001 and subsequent amendments). An algorithm of how these tests may be used is available on the website of the OIE Reference Laboratory in the UK<sup>6</sup>.

While many countries, and an OIE *ad hoc* Group on BSE tests, accept EU approval as an indicator of test performance, others have established their own evaluation mechanisms, most notably the United States of America, Canada and Japan (Canada's protocols for BSE surveillance<sup>7</sup>; National Veterinary Assay Laboratory, Ministry of Agriculture, Forestry and Fisheries, Outline of Regulation System of Veterinary Drugs in Japan<sup>8</sup>). The OIE also has an approval process and protocols for such evaluations are posted on the OIE web site: Validation and certification of Diagnostic Assays<sup>9</sup>, and the EU approval process has been accepted as the gold standard for future evaluations in terms of acceptable sensitivity and specificity.

The relative sensitivities of rapid tests, immunohistochemistry and other confirmatory methods have not been fully determined as, by definition, the tests cannot all be applied to identical samples, and the PrP<sup>Sc</sup> distribution is anatomically variable. (As a compromise, tissue homogenates or mixtures of finely chopped tissue may be used and provide some information, for certain types of tests.) Acknowledgement of this is particularly important in evaluating rapid test performance when testing animals that are not presenting clinical signs of BSE and are likely to have smaller, more restricted depositions of PrP<sup>Sc</sup> than cattle with more advanced disease. Rapid tests provide a means of initial screening for animals in the last few months of the incubation period (Arnold *et al.*, 2007), for example in surveys of post-mortem material collected from routinely slaughtered cattle. In countries conducting surveillance for the detection of the novel occurrence of BSE and in those countries in which a means of assessing the prevalence of BSE is considered necessary independent of the system of notification of suspect cases, these screening tests offer an efficient approach. Since their introduction for active screening in Europe from January 2001, such tests have been responsible for the identification of the majority of BSE-infected animals and are the preferred primary test. However, confirmation of a diagnosis of BSE ideally requires either the examination of fixed brain by immunohistochemistry or the application of an appropriate Western immunoblot protocol. In 2006, the OIE accepted that through their use in active surveillance programmes, commercial rapid tests have proved themselves to be very effective and consistent, provided they are performed by appropriately trained personnel. Indeed, at times they may out-perform the acknowledged standard of comparison if training and experience in the latter are deficient. Under such circumstances, it is now considered acceptable for diagnosis, even if not ideal for characterisation, for rapid tests to be used in combination for both primary screening in active or passive surveillance programmes and subsequent confirmation. It is essential however to ensure that the choice of primary and secondary test are compatible, and do not present a danger of generating false positive results through shared reagents. Consequently, an algorithm of preferred test combinations will be maintained on TSE-LAB-NET to assist those who wish to use this approach instead of histopathology and immunohistochemistry, or Western immunoblotting for confirmation. The combination of tests should include a Western blot method to generate useful complementary data that will assist in phenotypic characterisation of the sample in the absence of examination of fixed tissue. The confirmation should be carried out in a National Reference Laboratory.

The combination of the two rapid tests can only be used for the confirmation of a BSE case. A negative result by the secondary test is insufficient to define a case as negative following a primary positive result. BSE suspect cases with discordant rapid test results must therefore be investigated further using either the Western immunoblotting or IHC for the demonstration of PrP<sup>Sc</sup>, or if these methods are not available, by histopathology. If histopathology is unable to confirm the initial reactive result, samples should be submitted to an OIE Reference laboratory for further examination.

Although the test evaluation programmes conducted in Europe were in support of legislation on surveillance for BSE, the consequences are of relevance to other countries. The consequences of false-positive or false-negative results are so great that the introduction of new tests should be supported by thorough evaluation of test performance. Claims by test manufacturers should always be supported by data, ideally evaluated independently. It must be stressed that the process of full validation of all of these diagnostic methods for BSE has been restrained by the lack of a true gold standard and the consequent need to apply standards of comparison based on relatively small studies. There is therefore a continuing need for the publication of larger

---

6 <http://www.tse-lab-net.eu/documents/tse-oie-guide.pdf>

7 <http://www.inspection.gc.ca/english/anim/disemala/bseesb/surv/protoce.shtml>

8 <http://www.maff.go.jp/nval/english/pdf/outline130325.pdf>

9 <http://www.oie.int/en/our-scientific-expertise/certification-of-diagnostic-tests/background-information/>

scale studies of assay performance, and none of the data published so far equate with recognised procedures for test validation for other diseases.

### 1.3. Other diagnostic tests

BSE infectivity can be shown by inoculating mice with brain tissue from terminally affected cattle, but bioassay is impractical for routine diagnosis because of the long incubation period. It is, however, the nearest approach to a 'gold standard' for the characterisation of isolates, which has to be based on secondary biological properties in a standardised host, in the absence of an isolatable physical agent. Transgenic mice, such as those over-expressing the bovine PrP gene, offer bioassays with reduced incubation periods for BSE, but none as yet represent practical diagnostic tools.

Methods using *in-vitro* protein amplification are proving very sensitive for the detection of some prion diseases (Castilla *et al.*, 2006; Orru *et al.*, 2012), including C-type BSE (Murayama *et al.*, 2010), but have not yet been formally evaluated for application within statutory surveillance systems, although some have been successfully piloted for surveillance applications in humans (Lacroux *et al.*, 2014; Orru *et al.*, 2014).

### 1.4. Availability of diagnostic reagents and kits

As discussed previously (Section 1.2.5 above), diagnostic kits have been licensed for use in many countries and reagents are available commercially and from OIE reference and other laboratories with a TSE surveillance programme. Laboratories should preferably use kits listed on the OIE Register, or else kits that have been fully evaluated and validated by the relevant regulatory bodies.

## 2. Serological tests

The infectious agents of prion diseases do not induce a significant immune response in the host so serological methods are not applicable.

## C. REQUIREMENTS FOR VACCINES

There are no vaccines available.

## REFERENCES

- ARNOLD M.E., RYAN J.B.M., KONOLD T., SIMMONS M.M., SPENCER Y.I., WEAR A., CHAPLIN M., STACK M., CZUB S., MUELLER R., WEBB P.R., DAVIS A., SPIROPOULOS J., HOLDAWAY J., HAWKINS S.A.C., AUSTIN A.R. & WELLS G.A.H. (2007). Estimating the temporal relationship between PrP<sup>Sc</sup> detection and incubation period in experimental bovine spongiform encephalopathy (BSE) of cattle. *J. Gen. Virol.*, **88**, 3198–3208.
- BERINGUE V., BENCSIK A., LE DUR A., REINE F., LAI T.L., CHENAIS N., TILLY G., BIACABE A.-G., BARON T., VILOTTE J.-L. & LAUDE H. (2006). Isolation from cattle of a prion strain distinct from that causing bovine spongiform encephalopathy. *PLoS Pathogens*, **2**, 956–963.
- BIACABE A.G., LAPLANCHE J.L., RYDER S. & BARON T. (2004). Distinct molecular phenotypes in bovine prion diseases. *EMBO Rep.*, **5** (1), 110–115.
- BRUCE M.E., WILL R.G., IRONSIDE J.W., MCCONNELL I., DRUMMOND D., SUTTIE A., MCCARDLE L., CHREE A., HOPE J., BIRKETT C., COUSENS S., FRASER H. & BOSTOCK C.J. (1997). Transmissions to mice indicate that 'new variant' CJD is caused by the BSE agent. *Nature*, **389**, 498–501.
- CASALONE C., CARAMELLI M., CRESCIO M.I., SPENCER Y.I. & SIMMONS M.M. (2006). BSE immunohistochemical patterns in the brainstem: a comparison between UK and Italian cases. *Acta Neuropathol.*, **111**, 444–449.
- CASALONE C., ZANUSSO G., ACUTIS P., FERRARI S., CAPUCCI L., TAGLIAVINI F., MONACO S. & CARAMELLI M. (2004). Identification of a second bovine amyloidotic spongiform encephalopathy: Molecular similarities with sporadic Cruetzfeldt-Jacob disease. *Proc. Natl Acad. Sci. USA*, **101**, 3065–3670.
- CASTILLA J., SAA P., MORALES R., ABID K., MAUNDRELL K. & SOTO C. (2006). Protein misfolding cyclic amplification for diagnosis and prion propagation studies. *Methods Enzymol.*, **412**, 3–21.

- DEBEER S.O.S., BARON T.G.M. & BENCSIK A.A. (2002). Transmissible spongiform encephalopathy diagnosis using PrP immunohistochemistry on fixed but previously frozen brain samples. *J. Histochem. Cytochem.*, **50**, 611–616.
- EUROPEAN FOOD SAFETY AUTHORITY (EFSA). (2015). EFSA Panel on Biological Hazards: Scientific Opinion on a request for a review of a scientific publication concerning the zoonotic potential of ovine scrapie prions. *EFSA J.*, **13** (8), 4197.
- GAVIER-WIDEN D., WELLS G.A.H., SIMMONS M.M., WILESMITH J.W. & RYAN J.B.M. (2001). Histological observations on the brains of symptomless 7-year-old cattle. *J. Comp. Path.*, **124**, 52–59.
- HAYASHI H., TAKATA M., IWAMARU Y., USHIKI Y., KIMURA K.M., TAGAWA Y., SHINAGAWA M. & YOKOYAMA T. (2004). Effect of tissue deterioration on postmortem BSE diagnosis by immunobiochemical detection of an abnormal isoform of prion protein. *J. Vet. Med. Sci.*, **66**, 515–520.
- JACOB J.G., LANGEVELD J.P.M., BIACABE A.-G., ACUTIS P.-L., POLAK M.P., GAVIER-WIDEN D., BUSCHMANN A., CARAMELLI M., CASALONE C., MAZZA M., GROSCHUP M., ERKENS J.H.F., DAVIDSE A., VAN ZIJDERVELD F.G. & BARON T. (2007). Molecular discrimination of atypical Bovine Spongiform Encephalopathy strains in a geographical region spanning a wide area in Europe. *J. Clin. Microbiol.*, **45**, 1821–1829.
- KONOLD T., BONE G.E., CLIFFORD D., CHAPLIN M.J., CAWTHRAW S., STACK M.J. & SIMMONS M.M. (2012). Experimental H-type and L-type bovine spongiform encephalopathy in cattle: observation of two clinical syndromes and diagnostic challenges. *BMC Vet. Res.* **8**, 22.
- KONOLD T., BONE G., RYDER S., HAWKINS S.A., COURTIN F. & BERTHELIN-BAKER C. (2004). Clinical findings in 78 suspected cases of bovine spongiform encephalopathy in Great Britain. *Vet. Rec.*, **155**, 659–666.
- KONOLD T., PHELAN L.J., CLIFFORD D., CHAPLIN M.J., CAWTHRAW S., STACK M.J. & SIMMONS M.M. (2014). The pathological and molecular but not clinical phenotypes are maintained after second passage of experimental atypical bovine spongiform encephalopathy in cattle. *BMC Vet. Res.* **10**, 243.
- LACROUX C., COMOY E., MOUDJOU M., PERRET-LIAUDET A., LUGAN S., LITAISE C., SIMMONS H., JAS-DUVAL C., LANTIER I., BERINGUE V., GROSCHUP M., FICHET G., COSTES P., STREICHENBERGER N., LANTIER F., DESLYS J.P., VILETTE D. & ANDREOLETTI O. (2014). Preclinical detection of variant CJD and BSE prions in blood. *PLoS Pathog.*, **10**:e1004202.
- LOMBARDI G., CASALONE C., D'ANGELO A., GELMETTI D., TORCOLI G., BARBIERI I., CORONA C., FASOLI E., FARINAZZO A., FIORINI M., GELATI M., IULINI B., TAGLIAVINI F., FERRARI S., CARAMELLI M., MONACO S., CAPUCCI L. & ZANUSSO G. (2008). Intraspecies transmission of BASE induces clinical dullness and amyotrophic changes. *PLoS Pathogens*, **4**(5): e1000075.
- MONLEON E., MONZON M., HORTSELLS P., VARGAS A., BADIOLA J.J. (2003). Detection of PrP<sup>Sc</sup> in samples presenting a very advanced degree of autolysis (BSE liquid state) by immunocytochemistry. *J. Histochem. Cytochem.*, **51**, 15–18.
- MURAYAMA Y., YOSHIOKA M., MASUJIN K., OKADA H., IWAMARU Y., IMAMURA M., MATSUURA Y., FUKUDA S., ONOE S., YOKOYAMA T. & MOHRI S. (2010). Sulfated dextrans enhance *in vitro* amplification of bovine spongiform encephalopathy PrP(Sc) and enable ultrasensitive detection of bovine PrP(Sc). *PLoS One*, **5**, e13152.
- OKADA H., IWAMARU Y., IMAMURA M., MASUJIN K., MATSUURA Y., SHIMIZU Y., KASAI K., MOHRI S., YOKOYAMA T. & CZUB S. (2011). Experimental H-type bovine spongiform encephalopathy characterized by plaques and glial- and stellate-type prion protein deposits. *Vet. Res.*, **42**, 79. doi:10.1186/1297-9716-42-79
- ORRÚ C.D., BONGIANNI M., TONOLI G., FERRARI S., HUGHSON A.G., GROVEMAN B.R., FIORINI M., POCCHIARI M., MONACO S., CAUGHEY B. & ZANUSSO G. (2014). A test for Creutzfeldt-Jakob disease using nasal brushings. *N. Engl. J. Med.*, **371** (6), 519–529.
- ORRÚ C.D., WILHAM J.M., VASCELLARI S., HUGHSON A.G. & CAUGHEY B. (2012). New generation QuIC assays for prion seeding activity. *Prion*, **6**, 147–152. doi: 10.4161/pri.19430.
- PRINCE M.J., BAILEY J.A., BARROWMAN P.R., BISHOP K.J., CAMPBELL G.R. & WOOD J.M. (2003). Bovine spongiform encephalopathy. *Rev. sci. tech. Off. int. Epiz.*, **22**, 37–60 (English); 61–82 (French); 83–102 (Spanish).
- SCHALLER O., FATZER R., STACK M., CLARK J., COOLEY W., BIFFIGER K., EGLI S., DOHERR M., VANDEVELDE M., HEIM D., OESCH B. & MOSER M. (1999). Validation of a Western immunoblotting procedure for bovine PrP<sup>Sc</sup> detection and

its use as a rapid surveillance method for the diagnosis of bovine spongiform encephalopathy (BSE). *Acta Neuropathol. (Berl.)*, **98**, 437–443.

STACK M.J. (2004). Western immunoblotting techniques for the study of transmissible spongiform encephalopathies. In: *Techniques in Prion Research*, Lehmann S. & Grassi J., eds. Birkhauser, Basel, Switzerland. ISBN 3-7643-2415-5

SIMMONS M.M., HARRIS P., JEFFREY M., MEEK S.C., BLAMIRE I.W.H. & WELLS G.A.H. (1996). BSE in Great Britain: consistency of the neurohistopathological findings in two random annual samples of clinically suspect cases. *Vet. Rec.*, **138**, 175–177.

WELLS G.A.H. & WILESMITH J.W. (1995). The neuropathology and epidemiology of bovine spongiform encephalopathy. *Brain Pathol.*, **5**, 91–103.

WILESMITH J.W., HOINVILLE L.J., RYAN J.B.M. & SAYERS A.R. (1992). Bovine spongiform encephalopathy: aspects of the clinical picture and analyses of possible changes 1986–1990. *Vet. Rec.*, **130**, 197–201.

\*

\* \*

**NB:** There are OIE Reference Laboratories for Bovine spongiform encephalopathy (see Table in Part 4 of this *Terrestrial Manual* or consult the OIE Web site for the most up-to-date list: <http://www.oie.int/en/our-scientific-expertise/reference-laboratories/list-of-laboratories/> ).

Please contact the OIE Reference Laboratories for any further information on diagnostic tests and reagents for bovine spongiform encephalopathy