

Diseases of the European wildcat (*Felis silvestris* Schreber, 1777) in Great Britain

S. McORIST *

Summary: *The author describes an examination conducted in collaboration with the Nature Conservancy Council of Great Britain into the status with regard to disease, conservation and genetics of the European wildcat (Felis silvestris). Feline leukaemia virus (FeLV) infection was detected by positive enzyme-linked immunosorbent assay in blood from 2 of 23 wildcats and was tested and confirmed by FeLV isolation in one of the two cats. This is the first time the virus has been clearly demonstrated in a free-living felid, other than the domestic cat.*

Toxoplasmosis was detected in all cats tested, but neither feline coronavirus nor feline immunodeficiency virus was detected in any sample.

The genetic analysis indicated that only 8 of 42 wildcats tested were genetically distinct. These were mainly located in the western highlands of Scotland where "relict" populations may have survived. Interbreeding with domestic cats and persecution by trapping and hunting represent major threats to the survival of the European wildcat.

KEYWORDS: Feline leukaemia – *Felis silvestris* – Genetic analysis – Species hybridisation – United Kingdom – Wildcat.

INTRODUCTION

Significant disease syndromes in the domestic cat (*Felis catus*) are associated with viral infections. Feline leukaemia virus (FeLV) is a retrovirus which is associated with several neoplastic and non-neoplastic diseases. When susceptible cats are infected, they either mount a successful immune response and are transiently infected or become persistently viraemic and die from a clinical FeLV disease, such as lymphosarcoma (2). Feline infectious peritonitis virus (FIPV) is a coronavirus associated with serositis and vascular lesions, and feline immunodeficiency virus (FIV) is a lentivirus which induces immunosuppression (3, 12).

The European wildcat (*Felis silvestris* Schreber, 1777) occurs throughout Europe, but populations declined several hundred years ago as a result of habitat loss, especially in England and southern Scotland. However, the most significant factor

* Department of Veterinary Pathology, University of Edinburgh, Veterinary Field Station, Easter Bush, Midlothian EH25 9RG, Scotland, United Kingdom.

reducing the population was shooting and trapping, particularly during the nineteenth century when *F. silvestris* was lost from England and Wales. The lowest level of wildcat population in Scotland was reached in the early part of the twentieth century. Subsequently, recovery of the population has been due to a decrease in shooting and trapping, and increased availability of favourable habitats such as newly planted forests in Scotland (10).

Hybridisation of the wildcat with the domestic cat has probably been taking place since the spread of the latter across Europe in the Roman era. The extent of this hybridisation is thought to have increased during the twentieth century, due to the reduction in the population of wildcats and the increased numbers of domestic cats outside urban areas. Despite this fact, the wildcat population in Scotland is considered one of the "purest" in Europe, probably due to its remoteness (5, 14). As part of a study of genetic relationships among these cats, a survey of some viral and protozoal diseases was initiated.

DISEASE SURVEY

Animals and methods

Between 1982 and 1990, European wildcats in four study areas of Scotland (Fig. 1) were examined, as follows:

- lowland areas (A)
- the central highlands (B)
- the northern highlands (C)
- the western highlands (D).

Of twenty-three live wildcats collected, eight were held in open display enclosures at the Scottish Highland Wildlife Park. Five of these had been trapped elsewhere, but three had been bred on site from stock captured locally. A further wildcat which died at this site and nine wildcats collected as road kills were examined at necropsy. Fifteen other wildcats were trapped in highland and forest areas, and in wooded areas in the lowlands, often adjacent to arable land.

All live cats were tranquilised by a single intramuscular injection of ketamine hydrochloride (10 mg/kg) and xylazine (1.0 mg/kg). Flaccid muscle tone and moderate sedation occurred within 10-15 min, which allowed a full clinical examination and blood collection. All wildcats recovered fully within 30-45 min and were released to their site of collection or enclosure. Plasma samples taken after centrifugation of each blood sample were assayed for evidence of infection by feline viruses and *Toxoplasma gondii*. An indirect immunofluorescence assay incorporating the Wellcome strain of FIPV antigen was used to detect coronavirus antibody. A commercial indirect enzyme-linked immunosorbent assay (ELISA) was used to detect FIV antibody. The p27 antigen of FeLV was detected by ELISA (9). Any plasma sample which yielded a positive FeLV antigen result was subsequently inoculated onto feline cells in an attempt to isolate infectious virus. Infected cells were identified by the observation of cytopathic effects between 4 and 14 days, and the subgroup of any viral isolate was determined by an interference assay. Antibodies to *T. gondii* were detected by an indirect immunofluorescence assay incorporating formalinised *T. gondii* tachyzoites. All assays incorporated positive and negative controls obtained from domestic cats.

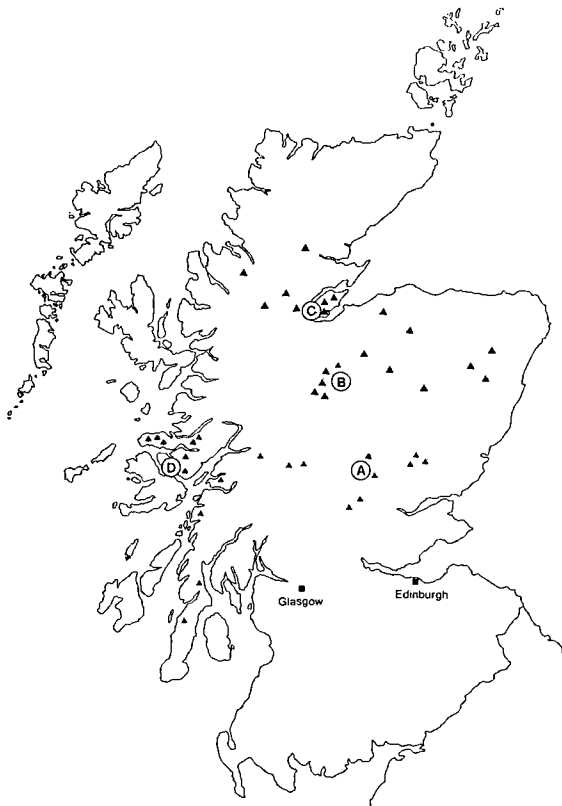


FIG. 1

Map of the northern half of Great Britain, illustrating sites of collection of wildcats in areas A (lowland), B (central highlands), C (northern highlands) and D (western highlands)

Results

Of the nine dead cats collected as road kills, one (a three-year-old female) had diffuse enlargement of the tonsils and of the submandibular, prescapular and parietal lymph nodes. Histological examination revealed diffuse hyperplasia of the germinal centres of the cortices of follicles in affected lymphoid tissue. All nine cats had lesions consistent with death by traumatic injury.

The cat which died at the Highland Park had severe chronic rhinotracheitis at post-mortem examination. Three of the live cats from this location had mucopurulent ocular and nasal discharges. Other clinical findings included lacerations probably due to fighting ($n = 2$) and colonies of fleas in the ears, identified as *Ctenocephalides* sp. ($n = 3$). The wildcats weighed between 2.5 and 5.5 kg and were assessed by body measurements to be aged between six months and three years.

All of the plasma samples were negative for antibodies to FIPV and FIV, and positive for antibodies to *T. gondii* (titres greater than 1/64). FeLV antigen was detected in two samples from the northern (C) and western (D) highlands. One sample (area D) was from a healthy, twelve-month-old male weighing 4 kg; FeLV of subgroup A was isolated from its blood.

GENETIC ANALYSIS

Methods

Genetic and molecular studies compared the extent of hybridisation of domestic cats and wildcats in various parts of Scotland (8). Briefly, restriction fragment length polymorphism using *Taq* 1 enzyme and actin gene probes detected distinctive deoxyribonucleic acid (DNA) characters in wildcats. Also, isoenzyme analysis using glucose phosphate isomerase in red blood cells, and complement fixation titres of blood albumin with domestic cat reagents gave immunological distance values (8).

Results

Wildcats in the north and west (Fig. 2) had the least relationship to domestic cats in the tests used and probably formed a separate genetic group, whereas the lowland and central highland wildcats had strong and moderate hybridisation respectively.



FIG. 2

A European wildcat photographed during the study in western Scotland in March 1989

DISCUSSION

This survey indicates that the European wildcat is susceptible to infection with feline leukaemia virus and "cat flu". Lesions of rhinotracheitis occurred in wildcats which had been kept in captive groups of two or three for periods of one to twelve months. The cold weather and close contact between wildcats at this site are likely to have exacerbated the disease (6). "Cat flu" is relatively common in large captive felids as well as in the domestic cat (4) indicating that the inciting viruses may have broad host ranges. The possible death of a wildcat from the disease indicates that it is a potential threat to

free-living wildcats, although factors associated with captivity may have an important role in determining the severity of clinical signs in infected animals.

FeLV infection was indicated in *F. silvestris* by isolation of virus and detection of antigen by ELISA. Feline leukaemia has previously been reported in exotic felids through positive ELISA results in a western cougar (*F. concolor*) and a clouded leopard (*Neofelis nebulosa*) kept in captivity (1, 11), and the virus was isolated from a leopard cell line (13). Further investigation in the latter study did not reveal evidence of FeLV in wild felids, although European wildcats were not examined. It is likely that these occasional infections resulted from interactions with domestic cats (1). Also, some caution is required in interpreting positive ELISA results, due to the possibility of false positive reactions.

Therefore, the infection reported here represents the first conclusive report of FeLV in a free-living non-domestic cat, apparently from transmission occurring in the wild. Whether the disease was transmitted to the wildcat from another wildcat or from a domestic cat is impossible to ascertain. Domestic cats are common in the sampling area in the west of Scotland and it is possible that infection occurred following an initial exposure to an infected domestic cat. However, it is also possible that FeLV may exist as a sustained infection in the remaining wildcats of Scotland and may pose a potential threat to this species. It is likely that the host range of FeLV could always have had the potential to include *F. silvestris*, which raises the possibility that other *Felis* species could become hosts. The prevalence of FeLV infection in *F. silvestris* (1 in 23, or 4.3%) is similar to that previously reported (5%) in surveys of domestic cats in Great Britain, although these were relatively small surveys (7).

The infected wildcats were in the northern and western area, where domestic cats are common and may have come into contact with the sampled animals. Comparisons of isoenzymes, DNA hybridisation and albumin heterogeneity in the wildcat samples in this study indicate that they have the least evidence of hybridisation with domestic cats. The possibility exists, therefore, that FeLV occurs as a sustained infection in some populations of wildcats rather than as an occasional infection acquired from domestic cats. FeLV is transmitted readily amongst young cats via infected body fluids (such as during fighting or mating). Such interactions are probably common among wildcats, and between wildcats and domestic cats in Scotland.

FeLV subgroup A is the strain most commonly isolated from domestic cats (11). FeLV is more commonly isolated in cats of one to five years of age and the latent period between FeLV infection and occurrence of severe clinical signs is likely to be two to four years. Therefore, the appearance of the latent infections in the wildcat population could be monitored prior to the appearance of clinical cases.

The absence of antibodies to FIPV or FIV suggests that these viruses may not actively circulate in free-living wildcats. However, FIV antibody is more likely to be found in older, male cats, which comprised only a small part of this survey. FIP has recently been diagnosed in captive European wildcats in a British zoological collection (unpublished findings).

The presence of antibodies to *T. gondii* in all samples suggests that this organism actively circulates in the wild. Wildcat faeces may therefore act as a potential source of infection for domestic species and man.

ACKNOWLEDGEMENTS

The author wishes to thank Drs O. Jarrett and D. Buxton for some analyses, and staff of the Nature Conservancy Council for assistance with the collection of samples.

*
* *

LES MALADIES DU CHAT FORESTIER EUROPÉEN (*FELIS SILVESTRIS* SCHREBER, 1777) EN GRANDE-BRETAGNE. – S. McOrist.

Résumé : Une étude entreprise en collaboration avec le Conseil pour la conservation de la nature en Grande-Bretagne a permis d'analyser les maladies, la conservation et les caractères génétiques du chat forestier européen (*Felis silvestris*). Des prélèvements sanguins de 23 chats ont été examinés et l'épreuve immuno-enzymatique a permis de mettre en évidence l'infection due au virus de la leucémie féline (FeLV) chez deux de ces chats. Le FeLV a été recherché et isolé chez l'un d'entre eux. Il s'agit de la première démonstration de la présence du virus chez un féliné en liberté autre que le chat domestique.

La toxoplasmose a été diagnostiquée chez tous les chats examinés ; en revanche, ni le coronavirus félin ni le virus de l'immunodéficience féline n'ont pu être mis en évidence dans les prélèvements.

L'analyse génétique a montré que seulement 8 des 42 chats forestiers étaient génétiquement différents. Ceux-ci provenaient essentiellement des Highlands occidentales de l'Ecosse où des populations « reliques » peuvent avoir survécu. Les croisements avec des chats domestiques, le piégeage et la chasse à outrance représentent les principales menaces pour la survie du chat forestier européen.

MOTS-CLÉS : Analyse génétique – Chat forestier – *Felis silvestris* – Hybridation des espèces – Leucémie féline – Royaume-Uni.

*
* *

ENFERMEDADES DEL GATO MONTÉS EUROPEO (*FELIS SILVESTRIS* SCHREBER, 1777) EN GRAN BRETAÑA. – S. McOrist.

Resumen: El autor describe un estudio realizado en colaboración con el Consejo de conservación de la naturaleza en Gran Bretaña sobre el estado sanitario, las condiciones de conservación y el patrimonio genético del gato montés europeo (*Felis silvestris*). Se analizaron muestras sanguíneas procedentes de veintitrés gatos y, a través del enzimo-inmunoensayo, se detectaron dos casos de infección por el virus de la leucemia felina; uno de estos dos casos se confirmó después mediante el aislamiento de dicho virus. Es la primera vez que se pone claramente de manifiesto la presencia de este virus en un féliné en libertad distinto del gato doméstico.

La toxoplasmosis se diagnosticó en todos los gatos examinados, pero el coronavirus felino y el virus de la inmunodeficiencia felina no se detectaron en ninguna muestra.

El análisis genético reveló que de los 42 gatos examinados sólo 8 eran genéticamente distintos. De estos últimos, la mayoría provenía de los Highlands

occidentales de Escocia, donde pueden haber sobrevivido poblaciones «reliquia». Los cruces con gatos domésticos, las capturas con trampas y la caza excesiva son los principales factores que amenazan la supervivencia del gato montés europeo.

PALABRAS CLAVE: Análisis genético – *Felis silvestris* – Gato montés – Hibridación de especies – Leucemia felina – Reino Unido.

*
* *

REFERENCES

1. CITINO S.B. (1986). – Transient FeLV viraemia in a clouded leopard. *Zoo Anim. Med.*, **17**, 5-7.
2. COTTER S.M., HARDY W.D. JR & ESSEX M. (1975). – Association of feline leukaemia virus with lymphosarcoma and other disorders in the cat. *J. Am. vet. med. Assoc.*, **166**, 449-454.
3. DISQUE D.F., CASE M.T. & YOUNGREN J.A. (1968). – Feline infectious peritonitis. *J. Am. vet. med. Assoc.*, **152**, 372-375.
4. FOWLER M.E. (1986). – Felidae. In *Zoo and wild animal medicine* (M.E. Fowler, ed.). W.B. Saunders, Philadelphia, 831-841.
5. FRENCH D.D., CORBETT L.K. & EASTERBEE N. (1988). – Morphological discriminants of Scottish wildcats (*Felis silvestris*), domestic cats (*Felis catus*) and their hybrids. *J. Zool.*, **214**, 235-259.
6. GASKELL R.M. & WARDLEY R.C. (1977). – Feline viral respiratory disease: a review with particular reference to its epizootiology and control. *J. small Anim. Pract.*, **19**, 1-16.
7. HOSIE M.J., ROBERTSON C. & JARRETT O. (1989). – Prevalence of feline leukaemia virus and antibodies to feline immunodeficiency virus in cats in the United Kingdom. *Vet. Rec.*, **125**, 293-397.
8. HUBBARD A.L., MCORIST S., JONES T.W., BOID R., SCOTT R. & EASTERBEE N. (1992). – Is survival of European wildcats in Britain threatened by interbreeding with domestic cats? *Biol. Cons.*, **61**, 203-208.
9. JARRETT O., GOLDER M.C. & WEIJER J. (1982). – A comparison of three methods of feline leukaemia virus diagnosis. *Vet. Rec.*, **110**, 325-329.
10. LANGLEY P.J.W. & YALDEN D.W. (1977). – The decline of the rarer carnivores in Great Britain during the nineteenth century. *Mammal Rev.*, **7**, 95-116.
11. MERIC S.M. (1984). – Suspected feline leukaemia virus infection and pancytopenia in a western cougar. *J. Am. vet. med. Assoc.*, **185**, 1390-1391.
12. PEDERSEN N.C., HO E.W., BROWN M.L. & YAMAMOTO J.K. (1987). – Isolation of feline T-lymphotropic lentivirus. *Science*, **235**, 790-794.
13. RASHEED S. & GARDNER M.B. (1981). – Isolation of feline leukaemia virus from a leopard cat cell line and search for retrovirus in wild felidae. *J. nat. Cancer Inst.*, **67**, 929-933.
14. SUMINSKI P. (1962). – Les caractères de la forme pure du chat sauvage *Felis silvestris* Schreber. *Arch. Sci.*, **15**, 277-296.